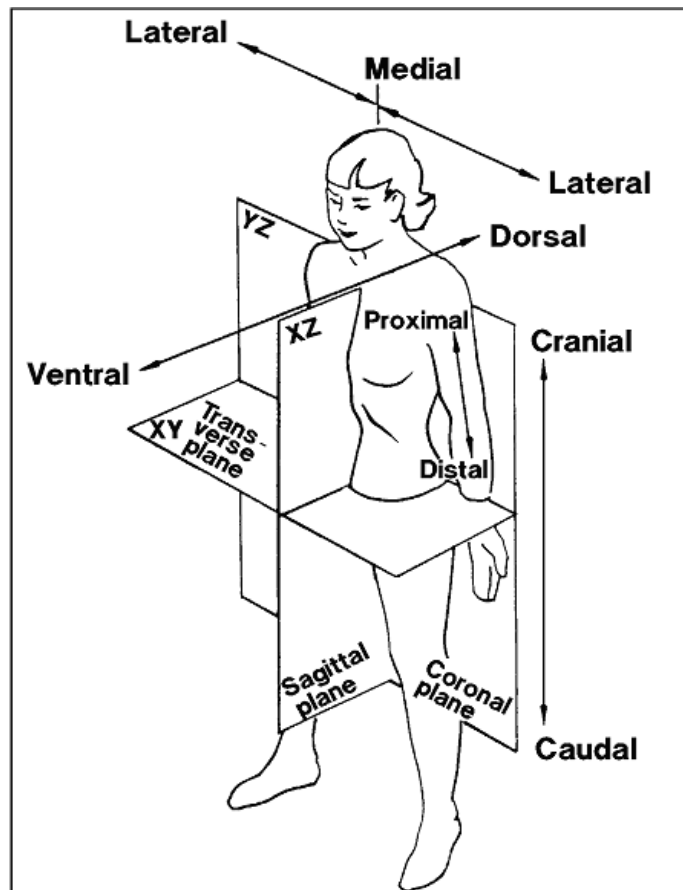


# CANCER TERMINOLOGY

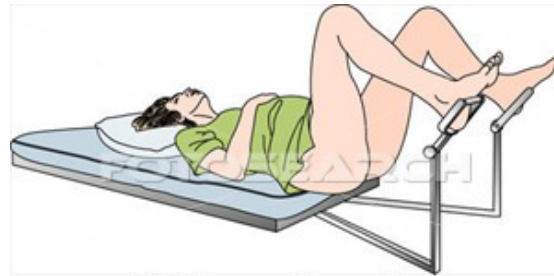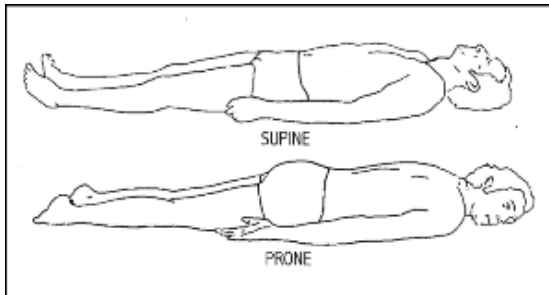
(Source: Book 3, SEER Self Instructional Manuals for Cancer Registrars)

## PLANES, POSITIONAL, AND DIRECTIONAL TERMS OF BODY



**Lateral**  
**Medial**  
**Ventral**  
**Dorsal**  
**Proximal**  
**Distal**  
**Cranial**  
**Caudal**  
**Sagittal**  
**Coronal**

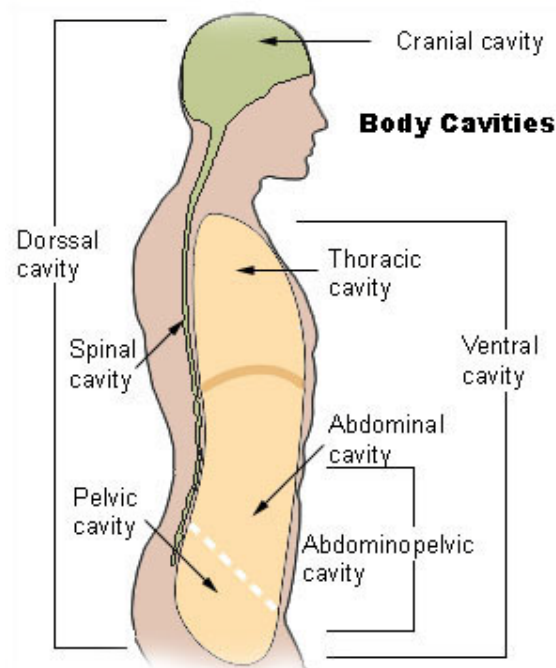
## PLANES, POSITIONAL, AND DIRECTIONAL TERMS OF BODY



nu214013 www.fotosearch.com

**Supine**  
**Prone**  
**Lithotomy**

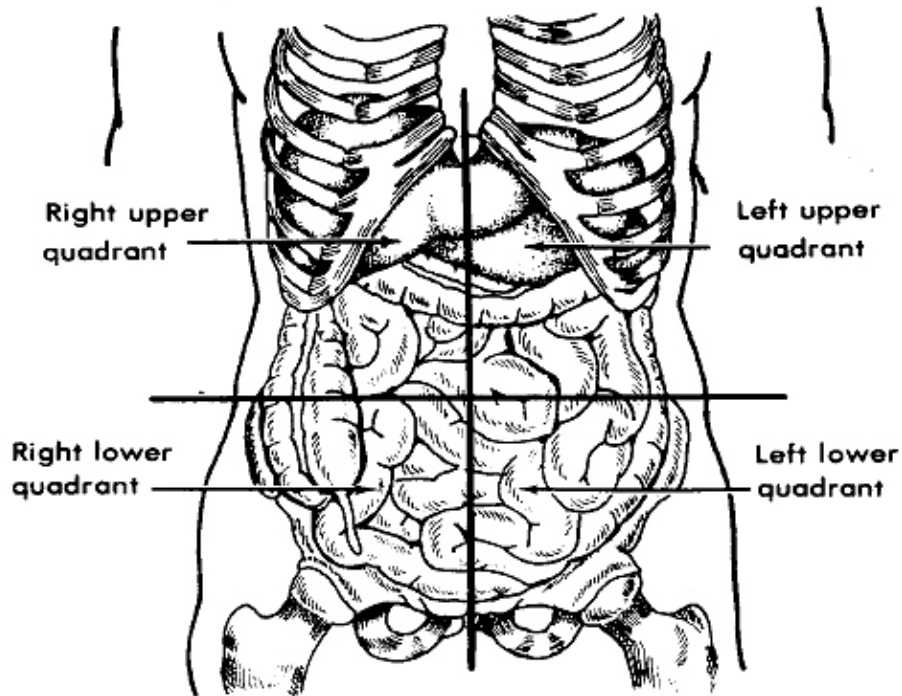
## CAVITIES OF THE BODY



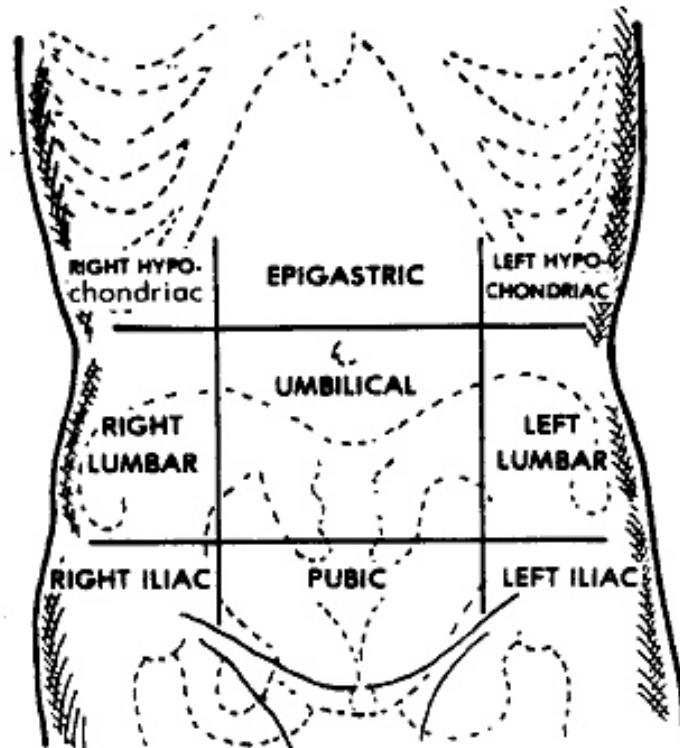
**Cranial**  
**Thoracic**  
**Spinal**  
**Abdominal**  
**Abdominopelvic**  
**Pelvic**

**Dorsal**  
**Ventral**

# ABDOMINAL QUADRANT



<p style="text-align: center;"><b>Right Upper (RUQ)</b></p> <p>Small bowel            Liver and Gallbladder            Pylorus            Duodenum            Head of Pancreas            Hepatic flexure of colon            Portions of ascending and transverse colon            Right adrenal gland            Portion of right kidney</p>	<p style="text-align: center;"><b>Left Upper (LUQ)</b></p> <p>Small bowel            Left lobe of liver            Spleen            Stomach            Body of Pancreas            Splenic flexure of colon            Portions of transverse and descending colon            Left adrenal gland            Portion of left kidney</p>
<p style="text-align: center;"><b>Right Lower (RLQ)</b></p> <p>Small bowel            Cecum and appendix            Portion of ascending colon            Lower pole of right kidney            Right ureter</p>	<p style="text-align: center;"><b>Left Lower (LLQ)</b></p> <p>Small bowel            Sigmoid colon            Portion of descending colon            Lower pole of left kidney            Left ureter</p>



<u>Right hypochondriac</u>	<u>Epigastric</u>	<u>Left hypochondriac</u>
Right lobe of liver Gallbladder Part of duodenum Hepatic flexure of colon Part of right kidney Suprarenal gland	Pyloric end of stomach Duodenum Pancreas Aorta Portion of liver	Stomach Spleen Tail of pancreas Splenic flexure of colon Upper pole of left kidney Suprarenal gland
<u>Right lumbar</u>	<u>Umbilical</u>	<u>Left lumbar</u>
Ascending colon Lower half of right kidney Part of duodenum and jejunum	Omentum Mesentery Transverse colon Lower part of duodenum Jejunum and ileum	Descending colon Lower half of left kidney Parts of jejunum and ileum
<u>Right iliac</u>	<u>Hypogastric or Pubic</u>	<u>Left iliac</u>
Cecum Appendix Lower end of ileum Right ureter Right ovary in female	Ileum Bladder	Sigmoid colon Left ureter Left ovary in female

